

We are IntechOpen, the world's leading publisher of Open Access books Built by scientists, for scientists

4,100

Open access books available

116,000

International authors and editors

120M

Downloads

Our authors are among the

154

Countries delivered to

TOP 1%

most cited scientists

12.2%

Contributors from top 500 universities



WEB OF SCIENCE™

Selection of our books indexed in the Book Citation Index
in Web of Science™ Core Collection (BKCI)

Interested in publishing with us?
Contact book.department@intechopen.com

Numbers displayed above are based on latest data collected.
For more information visit www.intechopen.com



Joint Instability as the Cause of Chronic Musculoskeletal Pain and Its Successful Treatment with Prolotherapy

Ross A. Hauser and Barbara A. Woldin

Additional information is available at the end of the chapter

<http://dx.doi.org/10.5772/intechopen.74384>

Abstract

This chapter is based on the premise that treatment with prolotherapy can greatly reduce chronic musculoskeletal pain, which affects more than 1 billion people worldwide. Although relatively unknown to mainstream medicine, prolotherapy has been used for decades to treat chronic musculoskeletal pain, doing so by correcting the underlying cause of that pain: joint instability due to ligament laxity. Discussions of joint instability, ligament physiology and biomechanics, compressive and shear forces, sites of instability, pain referral patterns, and ligament injury and healing demonstrate how they all interrelate to cause chronic pain. Treating chronic pain using nonsteroidal anti-inflammatory drugs, corticosteroids, and the rest, ice, compression, and elevation protocol actually inhibit the natural healing process of injured ligaments because they interrupt the inflammatory response, prevent joint swelling, and hinder cell proliferation, resulting in further ligament laxity and tissue regrowth that is inferior to native ligament tissue. Unlike conventional treatments, prolotherapy injects small volumes of an irritant solution into painful ligaments, tendons, joints, and surrounding joint spaces, initiating an inflammatory response which then attracts substances that promote normal cell and tissue growth. Their propagation stimulates the injured ligament to proliferate and grow at the injection sites, resulting in the regeneration of new tissue.

Keywords: chronic pain, joint instability, ligament laxity, prolotherapy, regenerative injection therapy

1. Introduction

“Keep people moving” is the mantra of the Global Alliance for Musculoskeletal Health—The Bone and Joint Decade (GAMH/BJD) 2010–2020, a global collaboration first launched in 2000 as the Bone and Joint Decade and dedicated to improving the health-related quality of life for

people with musculoskeletal disorders (MSKDs) throughout the world. A Bone and Joint Decade Global Minimum Standards of Care for Musculoskeletal Health was created to develop better treatment modalities according to evidence-based recommendations and will be focusing on two crucial areas—chronic pain and hip fractures [1]. The work of the Alliance has awakened the medical community to this urgency, resulting in a record number of research studies being published since 2002. Despite this, MSKDs remain a major cause of disability, ranking second worldwide and first in developed countries. Today, one in four people around the world suffer from long-standing loss of function and pain [2, 3]; Global Burden of Disease studies show that MSKDs cause 21.3% of all years lived with disability (YLDs) [4] and saw an increase of 61.6% in disability-adjusted life years (DALYs) from 1990 to 2016, with osteoarthritis showing the greatest increase [5]. DALY refers to the sum of YLDs and the years of life lost (YLLs) due to premature mortality. These data represent the enormous unmet need of finding effective ways to prevent and treat musculoskeletal conditions.

MSKDs are the most common cause of severe long-term pain [6]. Over 1.3 billion people worldwide are living with back pain, neck pain, osteoarthritis, or other painful musculoskeletal conditions [4]—a pandemic of epic proportions that modern medicine has been unable to rectify. That is because modern medicine has not identified or addressed the underlying cause of chronic musculoskeletal pain—namely, joint instability, which is the primary focus of this chapter, along with how to treat it successfully with prolotherapy.

2. Joint instability: the precursor to chronic pain

The human body has 360 joints, each of which contains at least two bones that are connected to one another by one or more ligaments. Joint instability occurs when there is excessive movement of these bones or increased speed of their motion relative to the other as tension is placed on the joint. This inability to maintain the relationship between adjacent bones under normal physiological forces puts extra pressure on intra-articular and surrounding joint structures, leading to joint degeneration, soft tissue damage or tears, and pain. Joints begin to degenerate or break down when the catabolic (destructive) processes exceed the anabolic (reparative) processes. Once the catabolic processes take over, the joint undergoes full cartilage loss, leaving it in a state of bone-on-bone without the cushioning effect of the cartilage tissue; thereafter, ligaments become overly stretched as they try to support the joint, leading to ligament laxity and excess motion in the joint. The end result is joint instability and disabling chronic musculoskeletal pain.

Each joint is designed to provide the precise amount of motion and stability needed for it to function as intended. Weight-bearing joints require more stability and, thus have less motion available. The hip is a major weight-bearing joint and, therefore, must be very stable to allow for ambulation. So too, is the lumbar spine, which must support the rest of the spinal column and the head. The facet joint capsule is the most richly innervated part of the spine in terms of nociception (pain perception) and proprioception (position sense) [7], and injury to the capsule ligaments there is the most common cause of spinal instability and spinal pain. In contrast, the

shoulder is the most dynamic joint in the body and must be very mobile, as it acts with the elbow to position the hand in space. The more intrinsically stable a joint is, the more it relies on bone and joint architecture for movement; the more intrinsically mobile a joint is, the more it relies on the ligaments for stability. While excess motion is a defining component of joint instability, the amount of force needed to produce any given range of motion in that joint becomes considerably less. That is why a second injury to the joint is much more likely to occur, even when the trauma seems relatively innocuous [8]. The integrity or lack thereof of the joint fluid, joint capsule, muscles, and tendons can also affect a joint's susceptibility to instability. Indeed, ligaments were never meant to stabilize the joints by themselves [9]. While ligaments are the primary passive joint stabilizers for most joints, muscles are the functional or dynamic joint stabilizers. The two are connected by the ligamento-muscular reflex. Therefore, when either structure becomes weakened, the other must take on more responsibility in maintaining the joint's stability.

Joint instability is caused by ligament laxity, which can occur after injury to one or more of the 900 ligaments that help support the joints of the body. Ligaments are dense bands of fibrous connective tissue that connect one bone to another and are the primary stabilizers of proper joint motion. When ligaments around a joint become weak, loose, or torn, they may not be able to hold the joint bones in place, causing one of the bones to partially dislocate or sublux. Subluxation occurs primarily because of laxity in a ligament and disrupts the connection of two adjacent bones in the joint. There are three primary ways that a ligament can become loose or torn: (1) trauma, a one-time substantial force, such as a whiplash injury; (2) overuse, a repetitive motion with a smaller intermittent force or creep, a steady load that puts a constant stretch on the ligament; (3) multidirectional instability, dislocation of a joint in different directions where the injury is severe enough to destroy the ligament. Tearing occurs when ligaments are stretched beyond their capacity to extend; once in this state, they are unable to return to their original length, even when the injurious force is removed [10].

2.1. Ligament physiology and biomechanics

Ligaments are taut bands of collagen that connect one bone to an adjacent bone to provide the primary stability in a joint. Collagen constitutes 70–80% of the dry weight of a ligament, the majority of which is type I collagen; the remaining constituents include elastin, glycoproteins, protein polysaccharides, glycolipids, fibrocytes, and water. Collagen has a relatively long turnover rate, with an average half-life of 300–500 days, which is slightly longer than that of bone. This means it can be several months before a ligament shows evidence of structural damage; this also affects its slow and often futile attempt to repair itself after injury [11]. One study demonstrated that ligaments were intact macroscopically at ultimate failure, but electron microscopy revealed widespread disruption of the collagen fibrils. However, once additional stress was applied, actual macroscopic disruption did occur, suggesting that microscopic failure of the collagen fibrils in grossly intact ligaments may be a significant cause of clinical instability [12].

Ligaments are viscoelastic tissues and thus, are pliant and flexible, allowing for natural movement of the attached bones they support; yet they are strong and inextensible when resistance to

applied forces is needed. Ligaments are able to do this because of a unique property known as crimping, whereby their collagen fibers are arranged in multiple directions so that they are aligned in an undulated or wavy pattern along their length when the ligament is relaxed, but become straighter when the ligament is stretched. Crimping allows ligaments to elongate and return to their original length without losing their strength or sustaining structural damage [13]. Although ligaments generally sustain tensile loads in one predominant direction, they are able to handle stresses in other directions, primarily because of their crimping behavior. When tension on a ligament increases, the collagen fibers progressively elongate (un-crimp) until all fibers are nearly linear, causing the ligament structure to become increasingly stiff. The stiffness of a material represents the material's ability to resist deformation and is found by dividing the change in load by the change in elongation. The signs and symptoms of joint instability reflect the loss of stiffness or strength in a ligament [14]. The crimping behavior of ligaments, as well as the interaction and cross-linking of collagen, elastin, and reticular fibers, is critical for normal joint mobility. These characteristics allow ligaments to have a limited range of strains over which they produce minimal resistance to movement. As a result, joints may easily be moved in certain directions and over certain ranges. Likewise, if a joint is displaced toward the outer limit of its normal range of motion, the strain of ligaments in that joint increases, causing recruitment of collagen fibers from their "crimp" state to a more straightened or stiff state. This allows the ligament to quickly increase its resistance to further elongation and stabilize the joint.

As viscoelastic tissues, ligaments also exhibit stress/strain behavior that is time-rate dependent and are stiffer and stronger at high-strain rather than low-strain rates. Therefore, ligaments are more likely to elongate under slower loading conditions, which would lower their risk of failure. Ligaments have a nonlinear, strain-stiffening structural response, which is thought to occur because of the crimp pattern of their collagen fibrils that elongate when small tensile loads are applied. As already mentioned, ligaments then become stiffer and stronger and, thus, larger forces are required to produce a given strain. Ligaments also possess a property known as creep, in which progressive elongation or a change in strain with constant load occurs overtime; this should not be confused with stress-relaxation, which occurs in a tissue that is stretched and held at a fixed length. In this latter state, the higher the strain or loading rate is, the larger the peak force/stress becomes and, thus, the greater the magnitude of the stress-relaxation. In contrast, creep is a constant state of stress with an increasing amount of strain and causes elongation over time when a constant force/stress is applied across the tissue [11]. Moreover, the extent of creep depends on the magnitude and duration of the applied stress, and the deformation or elongation may become so extensive that the tissue can no longer perform its function. In one study, the authors report that rat medial collateral ligaments were shown to exhibit consistent nonlinear behavior in which the rate of relaxation was dependent upon strain level and the rate of creep was dependent upon stress level [15].

While the primary function of ligaments is to prevent excessive joint motion, they have other important functions, including transmitting loads from bone to bone, mediating motions between opposing fibrocartilage and cartilage surfaces, acting as a joint-force sensor, and maintaining joint congruency [9]. Together, ligament function echoes one common theme: maintaining even stress across the joint surfaces. In doing so, ligaments also ensure that the stress placed across the joint surfaces is distributed over as large an area as possible, which

allows the joint and its surfaces to handle the maximum amount of pressure, force, and stress when the loads are compressive. However, when a ligament is injured, the joint forces are suddenly concentrated in one area of the joint, which predisposes the joint surfaces to break-down and injury. The body instinctively reacts to distribute these forces more evenly by causing the joint to swell. This creates extra joint fluid that helps to distribute the forces within the joint more evenly and temporarily stabilizes the joint. Acute ligament injuries almost always result in joint swelling. These injuries also cause severe muscle spasms and tightness, especially when the spinal capsular ligaments in the lower back and neck are injured. Like joint swelling, muscle spasms are the body's response to stabilizing an unstable joint and dissipating pressures across the joint.

Ligaments can become injured when stretched as little as 5–10%, with failure occurring at 13–32% elongation [16, 17]. Thus, when too large a force is put on a ligament, it can elongate to a point where the tissue becomes permanently overstretched; if the force is not released, the ligament can completely fail or tear. For instance, anterior cruciate ligaments have been shown to fail at forces between 1730 and 2160 N [18, 19], and most studies report cervical ligament failure at around 100 N [20].

When ligament laxity occurs, there is a disconnect between the tissue's form and the function in that the additional length of the stretched-out ligament causes a permanent mechanical weakening in the tissue [21]. Simply put, the ligament has lost its stiffening capacity and can no longer support the joint or dissipate the forces placed on it. Ligament laxity in a joint is measured as the motions of translation and rotation at a given force or torque. There is a direct relationship between the amount of ligament lengthening and the amount of joint play or laxity [20, 22].

2.2. Compressive versus shear or rotational forces

The degree to which a ligament can become damaged depends on the magnitude, direction, and speed of the force put on the tissue. Ligaments, articular cartilage, and intervertebral disks can withstand compressive forces that are magnitudes greater than shear or rotational forces, which have a catabolic or break-down effect on these structures [23–25]. Thus, ligaments are less able to handle extension forces, especially when they are rotational or shear forces. "Sideways" shear and rotational or torsional forces place greater demands on the joints and ligaments. As a result, these rotational-type forces are more likely to trigger an injury and generate pain. Once a ligament is injured, even a slight shear force can cause tremendous pressure to develop within the joints. In some ways, the body can compensate for this. For instance, the oblique orientation of the interspinous ligaments in the lumbar spine is more conducive to axial rotation, enabling the tissues to resist posterior shear off the superior vertebrae and impose anterior shear forces during full flexion. These ligaments are similar to the collateral ligament in the knee in that they follow an arc throughout flexion to control the vertebral rotation. This helps the facet joints remain in contact and glide with the rotation [26]. Facet joints provide stability to the spine by restricting the range of motion of the superior vertebrae with respect to the inferior vertebrae and protecting the motion segments of the spine from high extension rotations and large shear displacements in the anterior direction [27, 28].

The most injurious movements for the intervertebral disks in the spine are flexion and axial rotation, the combination of which puts the greatest amount of stress on the ligaments and disks. It is this combined motion that causes most acute disk herniations. Flexion itself causes the upper vertebra to move anteriorly, which can compromise the integrity of the disk. During flexion, the nucleus becomes displaced posteriorly and begins to press on the posterior fibers of the annulus, increasing their tension, and the inferior articular processes of the upper vertebra glide upwards, freeing themselves from the superior articular processes of the lower vertebra. This causes the facet joint capsule, capsular ligaments, and other ligaments of the vertebral arch to become stretched. The tension imposed on these ligaments finally limits extension. Axial rotation, on the other hand, produces a strong shearing force that stretches the capsular ligaments and pulls the facet joints apart, while causing tension in the oblique central fibers of the annulus to build to a maximum. The nucleus then becomes compressed and the internal pressure there rises in proportion to the degree of rotation. The combined motions of flexion and axial rotation can be traumatic, as they produce increasing pressure inside the nucleus, tearing the annulus, and driving the nucleus posteriorly through cracks in the disk's structure. The result is a herniated disk.

Degenerative disk disease (DDD) begins with injury to the ligaments of the capsular or posterior ligamentous complex. Once the ligaments are stretched, an increase in the shear, rotational, and torsional forces on the intervertebral disks occurs, which causes the disks to deteriorate more quickly than normal. This stretching has a similar effect on the capsular and posterior ligament complex itself, as it causes increases in those same forces in that area of the spine. When the posterior ligamentous complex can no longer stabilize motion segments in the spine, the amount of motion with shear, bending, or torsion there can increase by as much as 270% [29].

Spondylolysis and spondylolisthesis are similar disorders of the spine that usually develop in adolescence and are caused by shearing forces or repetitive loading and hyperflexion/hyperextension of the spine. These types of motions, which are common in adolescents who participate in sports, put abnormal amounts of stress on the pars interarticularis, a small segment of bone within the neural arch that connects the superior and inferior articular facets [30]. Repetitive microtraumas to the pars often result in a stress reaction or fracture initially but can progress to spondylolysis and then to spondylolisthesis if not treated.

2.3. Locating the joint instability

The key to curing chronic pain is locating the joint instability, which can be difficult because it is only visible through rotational or shear forces. Stationary MRIs show density changes in tissue and do not show joint instability. Newer technologies, such as ultrasound and digital motion X-ray (DMX), are able to provide a clearer image of a ligament's structure and function. Kinematic or functional computerized tomography (fCT) and magnetic resonance imaging (fMRI) scans, as well as digital motion X-ray, are able to depict lumbar and cervical instability during motion. These types of radiographs are much more diagnostic, especially when patients have signs and symptoms of spinal instability, yet have normal MRIs in a fixed position. Studies have demonstrated the ability of kinematic radiographs to show excess vertebral motions and thereby document instability in degenerative disk disease, spondylolisthesis, and radiculopathy [31–35].

Specific radiological changes that suggest spinal instability include disk narrowing with gas in the disk, traction spurs, and posterior joint and subluxation (abnormal rotatory alignment and abnormal separation of the spinous processes).

The source of chronic pain is not always the site of the instability and involves the kinetic chain (Figure 1). This term refers to the joints and joint structures in the spine and extremities that move or handle force with a certain motion or movement. More often than not, the instability is located in the joint closest to the site and the start of maximum pain perception, but it is not unusual for it to be in the second closest joint to the site and the start of maximum pain perception. This means that the instability is usually in the next joint up or down in the kinetic chain from the one where the pain is located. At times, the instability is in the second farthest joint away from the hub in the kinetic chain.

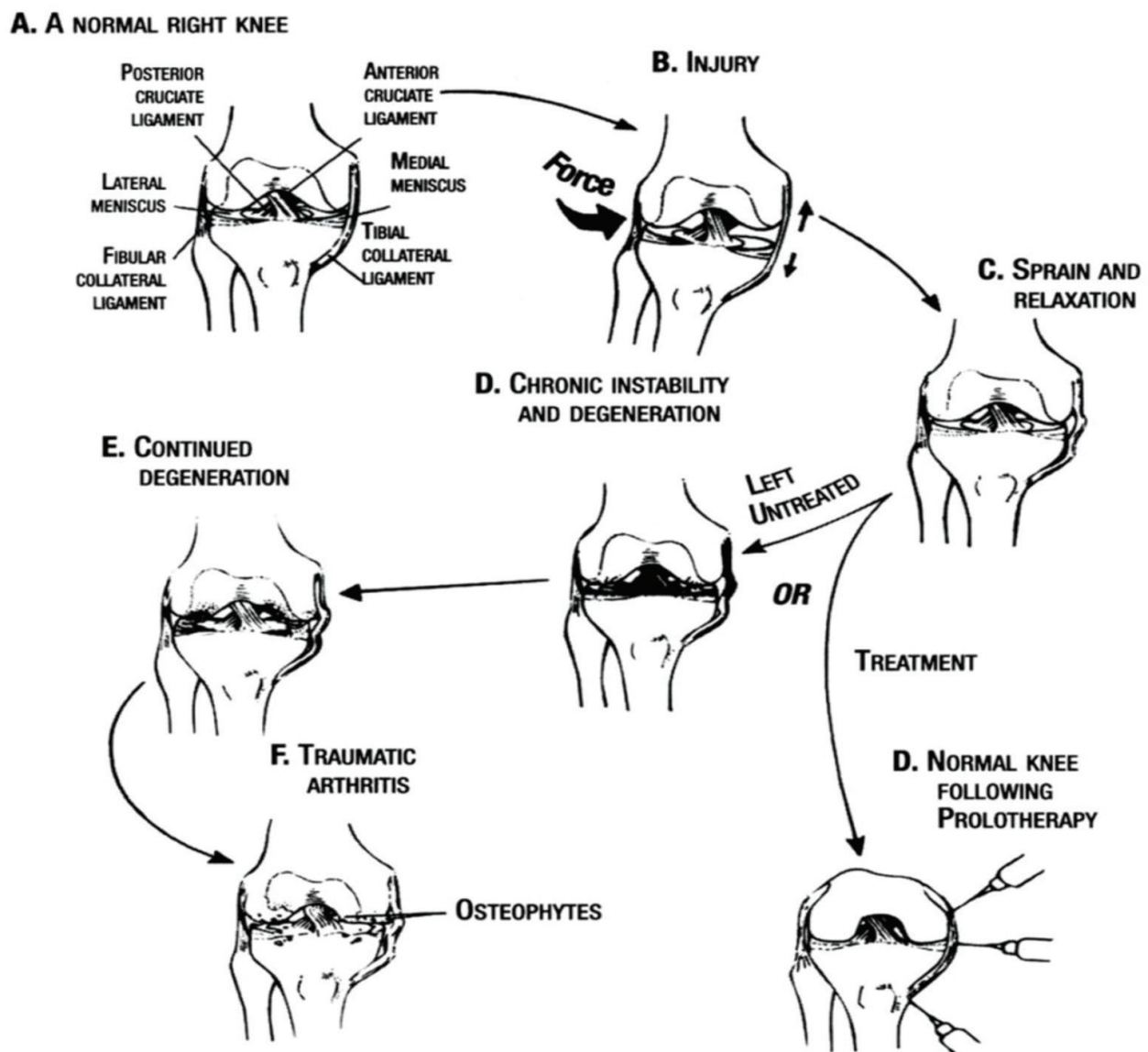


Figure 1. The kinetic chain-joint instability connection.

Ligaments contain an abundance of nerve receptors; thus, they are primary pain generators and act as the sensory organs of the joints by releasing pain signals to tell the brain what is occurring in and around the joint. Because of the high concentration of nerve endings in these tissues, even mild ligament injuries can cause severe pain (articular cartilage is devoid of nerve endings, so joint pain never originates from this tissue). Generally, when ligaments are stretched too far or at too fast a rate, their nerve receptors fire and transmit pain signals to where the instability might be. However, the tissues have well-known pain referral patterns that often deviate from this. For instance, injury to a ligament in the hip may cause instability there, but the pain can be referred all the way down into the big toe, or it can be referred to the inner or outer thigh, or to the buttock region if the muscles that cross or move the hip joint tighten and spasm. When external rotation of the hip causes pain, there is likely to be instability in the anterior hip joint since the motion would have stretched the nerve endings of the iliofemoral ligament, which stabilizes that joint.

Hearing cracking sounds in a joint or feeling that bones are rubbing together when certain movements are executed is completely abnormal in the context of human movements. These sensations are called crepitation and are signs of joint instability, especially if the crepitation in that location is associated with pain. Left unattended, crepitation can cause long-term pain to develop. As with earlier examples, the site of instability is not always obvious. A person may complain of pain at the base of the neck but feel crepitation in the mid-thoracic region. The actual source of the instability is likely in the upper back where the crepitation is, not in the neck where the pain is felt. Another sign of segmental spinal instability is gapping, which can occur when the capsular ligaments become lax or weakened. Gapping refers to an increase in the space between the facet joints and can be seen on functional X-rays and MRI or CT scans [36].

Sometimes joint instability and pain occur after certain types of surgery. For instance, spinal instability is a common complication of foraminotomy/laminectomy surgery because bony stabilizing structures are removed from the lower back during the procedure [37]. Other studies have shown that there is a significant increase in annulus stresses and segmental mobility when the facet joints are removed [38, 39]. Some types of orthopedic surgery can worsen any existing joint instability if the procedure removes stabilizing structures, such as bone spurs (chondroplasty), menisci (meniscectomy), labrum (labral resection), and intervertebral disks (microdiscectomy). Doing so puts more stress on the surrounding ligaments and stabilizing structures and increases the risk of further instability. Fusion surgery is a case in point. While the procedure is intended to improve stability, it often leads to future instability because additional forces are put on the segments above and below the fused segment. For example, after an L4-S1 fusion, instability is likely to develop in either the L3-L4 segment of the spine or the sacroiliac joints because they are both adjacent to the fused segment that can no longer move. This condition is called adjacent segment disease. As a result, the spinal instability is not resolved but is perpetuated as the adjacent segment disease “travels” up and down the spine. Spinal fusion is why adjacent segment disease and subsequent degenerative disk disease have become so prevalent [40]. People who are contemplating fusion surgery need to realize that the procedure permanently fuses the affected segments, limiting motion in that part of the spine for the rest of a person’s life.

The spine can move through six degrees-of-motion and the movements therein are either rotational or translational, meaning any excessive motion occurring between adjacent vertebrae can

move in a clockwise or counterclockwise direction (rotational) or in a direction that is to the right or left or forwards or backwards (translational). The ligaments are the tissues that regulate these adjacent vertebral rotations and translations. Given this, spinal motion can be a complex combination of translations and rotations and any subsequent instability can be translational or rotational in nature or a combination of both. The intervertebral disks are primary restraints against the compressive forces of gravity, whereas the posterior ligamentous complex and facet joints are primary constraints against bending and twisting movements. This is why one simple ligament injury in the spine can cause both disk degeneration and spinal instability. Clinically, spinal stability enables the spine to maintain its alignment during loading and allows the neural structures it encloses to be protected without causing pain [41]. It is the collective job of the disks, ligaments, bones, and muscles to keep the spinal column in proper alignment, so the spinal cord and nerves remain protected. However, if the spine no longer has adequately functioning biomechanical properties, clinical stability is lost, giving rise to spinal instability and pain.

When surgeons use the term “spinal instability” as a diagnosis, especially in the case of spinal fusion, they are usually referring to macroinstability, such as dislocation of a joint or a large movement of an adjacent bone. This occurs when there is complete disruption of a ligament. However, ligaments, other soft tissues, and disks can become injured by much smaller movements. These small-scale motions are called microinstability. Most chronic pain is caused by subfailure ligament injury, which occurs when the ligament is stretched out or becomes partially torn, but not completely disrupted. Just one or two ligaments need be affected to cause ligament laxity and the subsequent extra movement of adjacent bones. For instance, the capsular ligaments holding the facet joints in place can become lax or stretched out by as little as 1–2 mm. What is taking place here is clearly a process of microinstability.

2.4. Ligament healing: an oxymoron of sorts

Ligaments are notoriously poor healers because they are hypovascular, meaning they have a low blood supply, appearing white when compared with the highly vascularized red-colored muscles that can heal relatively quickly on their own. Although ligaments heal poorly, they do go through a specialized sequence of overlapping but distinct cellular events. This healing cascade consists of three consecutive phases that occur over time: the acute inflammatory phase, the proliferative or regenerative/repair phase, and the tissue-remodeling phase. Depending on the severity of injury to the ligament, it can be weeks or months and, sometimes, years before the process of healing is complete.

However, slow this course of healing may be, it is compounded by the extreme physiological and structural changes that ligaments undergo after injury, as well as by the complex and dynamic cellular processes that take place during healing. These deleterious events cause alterations in the biology and biomechanics of the injured ligament, leading to inadequate healing and tissue formation that is inferior to native ligament tissue. There is ample evidence to support this, as the literature has described remodeled ligament tissue as “grossly, histologically, biochemically, and biomechanically similar to scar tissue” [42–44] and “grossly, microscopically, and functionally different from normal tissues” [45]. The incomplete healing of the ligament and lower integrity of the new tissue results in ligament laxity, predisposing the joint

to further injury. This cycle of ligament injury and ensuing laxity causes joint instability, which then leads to chronic pain and diminished function, often culminating in osteoarthritis of the affected joint [14]. Therefore, once ligaments are stretched beyond a certain point, they do not regain their normal power and length, both of which are needed for a joint to become stable again and function normally.

2.5. Standard treatments do not pass muster

The RICE (rest, ice, compression, and elevation) protocol, nonsteroidal anti-inflammatory drugs (NSAIDs), and corticosteroids normally prescribed by modern medicine all put too much strain on the ligaments during the healing process and have been shown to inhibit ligament healing and contribute to long-term pain from incomplete recovery of ligament strength. Despite the longtime acceptance of rest and immobilization as a standard therapy after ligament injury, evidence is revealing that the absence of joint motion can have a dramatic effect on healing ligaments. Studies have shown that immobilizing a joint with an injured ligament can cause a number of adverse side effects, such as formation of synovial adhesions [46], increased collagen degradation, decreased collagen synthesis [47], and more disorganized collagen fibrils [48, 49]. Immobilization also contributes to the injured ligament's more catabolic state in that it disrupts loading, which alters matrix turnover in the ligament, as well as the degree of orientation of the matrix collagen fibrils within the tissue [50]. Consequently, matrix degradation begins to exceed matrix formation; however, what newly synthesized matrix there appears less well organized, and the ligament tissue itself is less stiff and weaker [14]. Prolonged limb immobilization also decreases the content of water and glycosaminoglycans in the ligament, adding to the ligament's loss in mass and strength [50]. Decreased ligament loading also has a profound effect on the strength of the fibro-osseous junction because immobilization causes subperiosteal osteoclasts to resorb much of the bony inserts of the ligament, causing a substantial decline in the tensile strength at the bone ligament interface [51]. Not surprisingly, there is growing evidence of a shift in protocol, as a systematic review found no controlled studies on soft tissue injuries favoring immobilization in the treatment of ligament injuries [52].

For many years, NSAIDs have also been a mainstay treatment for ligament injuries, especially in the case of acute sports injuries, but research has shown that these anti-inflammatory drugs are only mildly effective in relieving the symptoms of most muscle, ligament, and tendon injuries and are potentially deleterious to soft tissue healing [53–55]. Additionally, NSAIDs have been shown to accelerate the deterioration of articular cartilage and increase joint space in osteoarthritis [56, 57]. Furthermore, patients who are prescribed NSAIDs may feel no discomfort because of their analgesic effects and ignore any symptoms of ligament injury, which could cause further damage to the ligament and delay the tissue's healing. Studies have also been conducted on the cyclooxygenase-2 (COX-2) inhibitor class of NSAIDs, and researchers have concluded that the use of these particular medications inhibits ligament healing, leading to impaired mechanical strength in the tissue [58–60]. As a class, NSAIDs are no longer recommended for chronic soft tissue injuries and their use is cautioned in athletes who have ligament injuries. In the case of acute ligament injuries, NSAIDs should only be used for the shortest period of time possible, if used at all [61, 62].

There is good reason to expect that taking NSAIDs might have an adverse effect on healing since they inhibit inflammation, such as prostaglandin-induced inflammation, which is an early sequel in the cascade of injury-induced events. The inflammatory response normally results in the recruitment of cells into the injured area where they remove necrotic debris and initiate the healing process [14]. However, NSAIDs have been shown to specifically block the cyclooxygenase enzymes that catalyze the conversion of arachidonic acid to prostaglandins, which are thought to play a role in ligament healing [63].

There is also mounting evidence that corticosteroid injections into injured ligaments have an adverse effect on healing [18, 64–69]. Like NSAIDs, corticosteroids cause deterioration of articular cartilage [70–72]. Furthermore, corticosteroid injections into ligaments and tendons have been shown to inhibit fibroblast function, adversely affecting collagen synthesis [73]. Given the inhibitory effects corticosteroid injections have on ligament healing, reviews have cautioned against their use for treating ligament injuries, especially in athletes [14, 22].

As said earlier, one of the primary functions of ligaments is to ensure that the stress placed across the joint surfaces goes across the joint evenly and is distributed over as large an area as possible. To more evenly distribute these forces while the ligament is healing, the body causes the joint to swell, creating extra joint fluid to help dissipate the forces within the joint and temporarily stabilize the joint. When the RICE protocol, NSAIDs and corticosteroids are used, they prematurely reduce the swelling. Without the protective effect of joint fluid from swelling, the forces across the soft tissues remain concentrated in one spot, which can cause them to fibrillate and eventually crack. When loose pieces of cartilage (i.e., loose bodies) fall into the joint, it has experienced too much pressure. Therefore, joint swelling has a purpose—to stabilize the joint and distribute the forces within the joint evenly. When RICE, NSAIDs, and corticosteroids stop the swelling in the joint, they inhibit ligament healing and leave the joint vulnerable to further injury because the joint instability has not been corrected. Without resolution of the instability, the arthritic process accelerates further. Joint instability can be diagnosed on physical examination in the hands of an experienced prolotherapist who has the palpatory skills to detect evidence of joint laxity or a loose-end feel to the ligament. End-feel is a subjective measure of the elasticity of tissue but can be quantified as the mechanical property of stiffness, which is calculated as the change in the applied force divided by the resulting change in position length.

3. Prolotherapy: the right treatment for resolving joint instability and chronic pain

Prolotherapy, also referred to as proliferation therapy or regenerative injection therapy (RIT), is a technique in which substances that promote growth of normal cells or tissues are propagated through the injection of small volumes of an irritant solution into painful ligaments, tendon insertions, joints, and in the surrounding joint spaces over several treatment sessions [74–76]. This stimulates the ligaments and tendons to proliferate and grow at the injection sites, naturally promoting the rejuvenation of new tissue. Dr. George S. Hackett, who was the pioneer of

prolotherapy and coined the term Prolotherapy, described the procedure as such: “The treatment consists of the injection of a solution within the relaxed ligament and tendon which will stimulate the production of new fibrous tissue and bone cells that will strengthen the ‘weld’ of fibrous tissue and bone to stabilize the articulation and permanently eliminate the disability” [78].

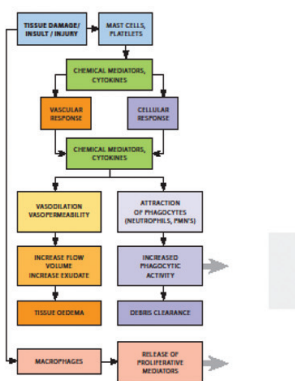
The injected substance (proliferant) used in prolotherapy is intended to mimic the body’s natural healing process by initiating a local inflammatory response, which triggers a healing cascade characterized by the release of growth factors and collagen deposition, leading to proliferation, ligament tissue remodeling, and strengthening of new tissue (**Figure 2**) and resulting in a return of function and joint stability; with this course of treatment comes a reduction in pain [78, 79]. Prolotherapy treats the enthesis, which is where ligaments and tendons attach to bone; the fibro-osseous junction is the area where the injection is administered. Comprehensive prolotherapy refers to treatment of all of the significant stabilizing structures of the joint, as well as the ligaments and addresses what is at the core of chronic musculoskeletal pain: joint instability due to ligament injury and its subsequent weakness/laxity.

The most common proliferating solution used in prolotherapy is dextrose, a sugar found naturally in the body as D-glucose, which cells need to survive. Dextrose offers many benefits as a proliferant for musculoskeletal conditions and pain: it is a normal component of blood chemistry, it is water soluble and readily available, it has a high safety profile and is considered GRAS

The Biology of Prolotherapy

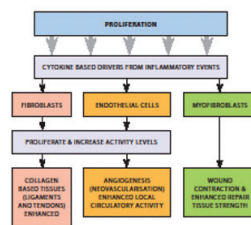
Inflammatory Cascade.

After tissue damage by injury, the body attempts to heal the area by mediating this cascade. When the body is unable to heal itself, which is often the case when avascular (no or little blood supply) tissues such as ligaments, tendons, cartilage and fibrocartilage (meniscus and labrum) are injured, Prolotherapy is utilized to stimulate healing.



Proliferation Cascade.

Prolotherapy stimulates healing via inflammation. After Prolotherapy solutions are injected into the injury site, a cellular reaction takes place in which various cells including fibroblasts, endothelial cells and myofibroblasts form new blood vessels and ultimately lay down collagen which enhances tissue repair and strength.



Tissue Remodeling Cascade.

The final phase of healing is tissue remodeling. For many months after an injury or Prolotherapy, tissue continues to remodel. The new tissue that results looks and functions very closely to the original tissue before the injury. Once the tissue strength approaches that of the normal parent tissue, pain resolves.

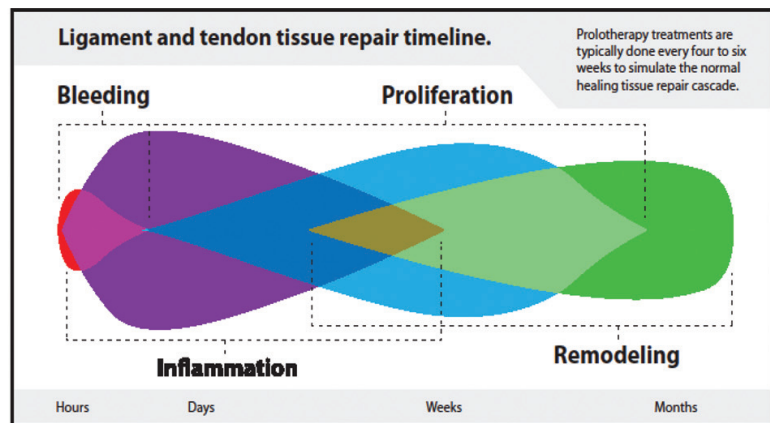
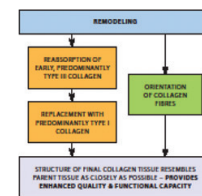


Figure 2. The biology of prolotherapy.

(generally recognized as safe) by the FDA. Other solutions that can be used in prolotherapy include pumice, P2G (phenol, glycerin, glucose), sodium morrhuate, polidocanol, sodium tetradecyl sulfate, manganese, zinc, and human growth hormone, as well as platelet-rich plasma, bone marrow, and lipoaspirate, which are forms of cellular prolotherapy and used for severe ligaments injuries.

The pioneering work of Dr. Hackett during the 1950s established a clear link between ligaments and joint pain by identifying ligaments as the main source of chronic musculoskeletal pain and then formalized prolotherapy as a viable therapeutic strategy to treat ligamentous laxity and related musculoskeletal conditions [77]. Today, prolotherapy is known to relieve pain by initiating healing and repair via an inflammatory healing cascade, wherein growth factors are released [80–87]. The release of these growth factors by prolotherapy induces ligament and tendon hypertrophy and strengthening [88–91], reduces neurogenic inflammation [92–94], and stabilizes unstable joints [89–91, 95, 96]. Prolotherapy is effective in reducing, and often eliminating, musculoskeletal pain in the joints of the body [77, 97–108].

Prolotherapy is a natural injection therapy that stimulates the body's response to injury and jumpstarts the repair process, resulting in the proliferation of cells that regenerate and strengthen ligaments, tendons, and other soft tissue structures associated with joint instability and chronic pain. The outcome of prolotherapy is the repair of tissues and strengthening of the joint-stabilizing structures, after which chronic pain subsides. There are several types of prolotherapy: comprehensive or Hackett-Hemwall prolotherapy, D-glucose or dextrose prolotherapy, and cellular prolotherapy, including bone marrow aspirates and platelet-rich plasma (PRP).

4. Conclusion

A review of the published literature indicates that prolotherapy is one of the safest and most effective treatment options for the billion or more people suffering from chronic musculoskeletal pain today. Unlike other pain therapies, prolotherapy strengthens and tightens ligaments that have become loose or lax and restores stability to unstable joints, relieving people of their pain and allowing them to return to an active lifestyle. The authors stand by their premise that prolotherapy is the best type of treatment for resolving the real cause of almost all chronic musculoskeletal pain: joint instability.

Author details

Ross A. Hauser¹ and Barbara A. Woldin^{2*}

*Address all correspondence to: barbwoldin@comcast.net

1 Caring Medical Regenerative Medicine Clinics, Fort Myers, Florida, USA

2 Caring Medical and Rehabilitation, Fort Myers, Florida, USA

References

- [1] The Global Alliance for Musculoskeletal Health. <http://bjdonline.org/prevention-and-control/>. [Accessed: October 12, 2017]
- [2] The Global Alliance for Musculoskeletal Health. <http://bjdonline.org/call-for-action/>. [Accessed: October 12, 2017]
- [3] The Global Alliance for Musculoskeletal Health. <http://bjdonline.org/public-and-patient-education/>. [Accessed: October 12, 2017]
- [4] GBD 2016 DALYs and HALE Collaborators. Global, regional, and national disability-adjusted life-years (DALYs) for 333 diseases and injuries and healthy life expectancy (HALE) for 195 countries and territories, 1990–2016: A systematic analysis for the Global Burden of Disease Study 2016. *Lancet*. 2017;**390**:1260-1344
- [5] GBD 2016 Disease and Injury Incidence and Prevalence Collaborators. Global, regional, and national incidence, prevalence, and years lived with disability for 328 diseases and injuries for 195 countries, 1990–2016: A systematic analysis for the global burden of disease study 2016. *Lancet*. 2017;**390**(10100):1211-1259
- [6] Palazzo C, Ravaud J-F, Papelard A, Ravaud P, Poiraud S. The burden of musculoskeletal conditions. *PLoS One*. 2014 Mar 4;**9**(3):e90633. DOI: 10.1371/journal.pone.0090633
- [7] Haheer TR, O'Brien M, Dryer JW, Nucci R, Zipnick R, Leone DJ. The role of lumbar facet joints in spinal stability. Identification of alternative paths of loading. *Spine (Phila Pa 1976)*. 1994;**19**(23):2667-2670
- [8] Kovalski JE, Heitman RJ, Gurchiek LR, Hollis JM, Liu W, Pearsall AW IV. Joint stability characteristics of the ankle complex after lateral ligamentous injury, part 1: A laboratory comparison using arthrometric measurement. *Journal of Athletic Training*. 2014;**49**(2): 192-197
- [9] Kjaer M, Jørgensen NR, Heinemeier K, Magnusson SP. Exercise and regulation of bone and collagen tissue biology. In: Bouchard C, editor. *Progress in Molecular Biology and Translational Science*. Vol. 135. Burlington, VT: Academic Press; 2015. pp. 259-291
- [10] Hubbard TM, Cordova M. Mechanical instability after an acute ankle sprain. *Archives of Physical Medicine and Rehabilitation*. 2009;**90**(7):1142-1146
- [11] Pal S. Mechanical properties of biological materials. In: *Design of Artificial Human Joints & Organs*. Boston, MA: Springer; 2014. pp. 23-40
- [12] Kennedy JC, Hawkins RJ, Willis RB, Danylchuck KD. Tension studies of human knee ligaments. Yield point, ultimate failure, and disruption of the cruciate and tibial collateral ligaments. *Journal of Bone and Joint Surgery. American Volume*. 1976;**58**(3):350-355
- [13] Frank CB. Ligament structure, physiology and function. *Journal of Musculoskeletal & Neuronal Interactions*. 2004;**4**(2):199-201

- [14] Hauser RA, Dolan EE, Phillips HJ, Newlin AC, Moore RE, Woldin BA. Ligament injury and healing: A review of current clinical diagnostics and therapeutics. *Open Rehabilitation Journal*. 2013;**6**:1-20
- [15] Provenzano P, Lakes R, Keenan T, Vanderby R Jr. Nonlinear ligament viscoelasticity. *Annals of Biomedical Engineering*. 2001;**29**:908-914
- [16] White AA, Panjabi MM, editors. *Clinical Biomechanics of the Spine*. 2nd ed. Philadelphia, PA: JB Lippincott; 1990
- [17] Chazal J, Tanguy A, Bourges M, et al. Biomechanical properties of spinal ligaments and a histological study of the supraspinal ligaments in traction. *Journal of Biomechanics*. 1985;**18**(3):167-176
- [18] Noyes FR, Grood ES. The strength of the anterior cruciate ligament in humans and Rhesus monkeys. *Journal of Bone and Joint Surgery: American Volume*. 1976;**58**(8):1074-1082
- [19] Woo SL, Hollis JM, Adams DJ, Lyon RM, Takai S. Tensile properties of the human femur-anterior cruciate ligament-tibia complex. The effects of specimen age and orientation. *American Journal of Sports Medicine*. 1991;**19**(3):217-225
- [20] Steilen D, Hauser R, Woldin B, Sawyer S. Chronic neck pain: Making the connection between capsular ligament laxity and cervical instability. *Open Orthopaedics Journal*. 2014;**8**:326-345
- [21] Hintermann B. Biomechanics of ligaments in ankle instability. In: Nyska M, Mann G, editors. *The Unstable Ankle*. Champaign, IL: Human Kinetics; 2002. pp. 27-35
- [22] Hauser R, Blakemore P, Wang J, Steilen D. Structural basis of joint instability as cause of chronic musculoskeletal pain and its successful treatment with regenerative injection therapy (prolotherapy). *Open Pain Journal*. 2014;**7**:9-22
- [23] Setton LA, Chen J. Mechanobiology of the intervertebral disc and relevance to disc degeneration. *Journal of Bone and Joint Surgery: American Volume*. 2006;**88**(Suppl 2):52-57
- [24] Smith RL, Carter DR, Schurman DJ. Pressure and shear differentially alter human articular chondrocyte metabolism: A review. *Clinical Orthopaedics and Related Research*. Nov 2004;(427 Suppl):S89-S95
- [25] Smith RL, Trindade MC, Ikenoue T, et al. Effects of shear stress on articular cartilage metabolism. *Biorheology*. 2000;**37**:95-107
- [26] Heylings DJ. Supraspinous and interspinous ligaments of the human lumbar spine. *Journal of Anatomy*. 1978;**125**(Pt 1):127-131
- [27] Lorenz M, Patwardhan A, Vanderby R. Load-bearing characteristics of lumbar facets in normal and surgically altered spinal segments. *Spine (Phila Pa 1976)*. 1983;**8**(2):122-130
- [28] Posner I, White A, Edwards WT, Hayes WC. A biomechanical analysis of the clinical stability of the lumbar and lumbosacral spine. *Spine (Phila Pa 1976)*. 1982;**7**:374-389

- [29] McGlashen KM, Miller JA, Schultz AB, Andersson GB. Load displacement behavior of the human lumbo-sacral joint. *Journal of Orthopaedic Research*. 1987;**5**(4):488-496
- [30] Bergmann TF, Hyde TE, Yochum TR. Active or inactive spondylolysis and/or spondylolisthesis: What's the real cause of back pain? *Journal of the Neuromusculoskeletal System*. 2002;**10**:70-78
- [31] Jang SY, Kong MH, Hymanson HJ, Jin TK, Song KW, Wang JC. Radiographic parameters of segmental instability in lumbar spine using kinetic MRI. *Journal of Korean Neurosurgical Society*. 2009;**45**:24-31
- [32] Takayanagi K, Takahashi K, Yamagata M, Moriya H, Kitahara H, Tamaki T. Using cineradiography for continuous dynamic-motion analysis of the lumbar spine. *Spine (Phila Pa 1976)*. 2001;**26**(17):1858-1865
- [33] Li W, Wang S, Xia Q, et al. Lumbar facet joint motion in patients with degenerative disc disease at affected and adjacent levels: An in vivo biomechanical study. *Spine (Phila Pa 1976)*. 2011;**36**(10):E629-E637
- [34] Ellingson AM, Nuckley DJ. Altered helical axis patterns of the lumbar spine indicate increased instability with disc degeneration. *Journal of Biomechanics*. 2015;**48**:361-369
- [35] Phan KH, Daubs MD, Kupperman AI, Scott TP, Wang JC. Kinematic analysis of diseased and adjacent segments in degenerative lumbar spondylolisthesis. *Spine Journal*. 2015;**15**:230-237
- [36] Taylor JR, O'Sullivan PB. Lumbar segmental instability: Pathology, diagnosis and conservative management. In: Twomey LT, Taylor JR, editors. *Physical Therapy of the Lower Back*. 3rd ed. Philadelphia, PA: Churchill Livingstone; 2000. pp. 201-247
- [37] Hilibrand AS, Robbins M. Adjacent segment degeneration and adjacent segment disease: The consequences of spinal fusion? *Spine Journal*. 2004;**4**(6 Suppl):190S-194S
- [38] Kumaresan S, Yoganandan N, Pintar EA. Finite element analysis of anterior cervical spine interbody fusion. *Biomedical Materials and Engineering*. 1997;**7**:221-230
- [39] Voo LM, Kumaresan S, Yoganandan N, Pintar FA, Cusick JF. Finite element analysis of cervical facetectomy. *Spine (Phila Pa 1976)*. 1997;**22**:964-969
- [40] Mitsunaga LK, Klineberg EO, Gupta MC. Laminoplasty techniques for the treatment of multilevel cervical stenosis. *Advances in Orthopedics*. Published online Mar 6 2012. DOI: 10.1155/2012/307916 Accessed: October 10, 2017
- [41] Hirsch C, Ingelmark BE, Miller M. Anatomical basis for low back pain. Studies on the presence of sensory nerve endings in ligamentous, capsular and intervertebral disc structures in the human lumbar spine. *Acta Orthopaedica Scandinavica*. 1963;**33**:1-17
- [42] Frank C, Shrive N, Bray R. Ligament healing: A review of some current clinical and experimental concepts. *Iowa Orthopaedic Journal*. 1992;**12**:21-28

- [43] Jack EA. Experimental rupture of the medial collateral ligament of the knee. *Journal of Bone & Joint Surgery*. 1950;**32**(B):306
- [44] Fang HC, Hu CH, Miltner LJ. Experimental joint sprain pathologic study. *Archives of Surgery*. 1937;**35**:234
- [45] Frank C, Shrive N, Hiraoka H, Nakamura N, Kaneda Y, Hart D. Optimization of the biology of soft tissue repair. *Journal of Science and Medicine in Sport*. 1999;**2**(3):190-210
- [46] Woo SL, Matthews JV, Akeson WH, Amiel D, Convery FR. Connective tissue response to immobility. Correlative study of biomechanical and biochemical measurements of normal and immobilized rabbit knees. *Arthritis & Rheumatology*. 1975;**18**:257-264
- [47] West RV, Fu FH. Soft-tissue physiology and repair. In: Vaccaro AR, editor. *Orthopaedic Knowledge Update 8*. Rosemont, IL: Am Academy of Orthopaedic Surgeons; 2005. pp. 15-27
- [48] Woo SL, Abramowitch SD, Kilger R, Liang R. Biomechanics of knee ligaments: Injury, healing, and repair. *Journal of Biomechanics*. 2006;**39**:1-20
- [49] Woo SL, Gomez MA, Sites TJ, Newton PO, Orlando CA, Akeson WH. The biomechanical and morphological changes in the medial collateral ligament of the rabbit after immobilization and remobilization. *Journal of Bone and Joint Surgery. American Volume*. 1987;**69**(8):1200-1211
- [50] Vailas AC, Tipton CM, Matthes RD, Gart M. Physical activity and its influence on the repair process of medial collateral ligaments. *Connective Tissue Research*. 1981;**9**(1):25-31
- [51] Buckwalter JA. Activity vs. rest in the treatment of bone, soft tissue, and joint injuries. *Iowa Orthopaedic Journal*. 1995;**15**:29-42
- [52] Nash CE, Mickan SM, Del Mar CB, Glasziou PP. Resting injured limbs delays recovery: A systematic review. *Journal of Family Practice*. 2004;**53**(9):706-712
- [53] Mehallo CJ, Drezner JA, Bytowski JR. Practical management: Nonsteroidal anti-inflammatory drug use in athletic injuries. *Clinical Journal of Sport Medicine*. 2006;**16**:170-174
- [54] Dahners LE, Mullis BH. Effects of nonsteroidal anti-inflammatory drugs on bone formation and soft-tissue healing. *Journal of the American Academy of Orthopaedic Surgeons*. 2004;**12**:139-143
- [55] U.S. Food and Drug Administration. Public Health Advisory: Non-Steroidal Anti-Inflammatory Drug Products (NSAIDs). Medication Guide For Non-Steroidal Anti-Inflammatory Drugs (NSAIDs). <https://www.fda.gov/downloads/Drugs/DrugSafety/ucm089162.pdf>. [Accessed: October 10, 2017]
- [56] Hauser RA. The acceleration of articular cartilage degeneration in osteoarthritis by nonsteroidal anti-inflammatory drugs. *Journal of Prolotherapy*. 2010;**1**(2):305-322
- [57] Huskisson HC, Berry H, Gishen P, Jubb RW, Whitehead J. Effects of anti-inflammatory drugs on the progression of osteoarthritis of the knee. LINK Study Group. Longitudinal

- investigation of nonsteroidal antiinflammatory drugs in knee osteoarthritis. *Journal of Rheumatology*. 1995;**22**(10):1941-1946
- [58] Elder CL, Dahners LE, Weinhold PS. A cyclooxygenase-2 inhibitor impairs ligament healing in the rat. *American Journal of Sports Medicine*. 2001;**29**:801-810
- [59] Warden SJ, Avin KG, Beck EM, DeWolf ME, Hagemer MA, Martin KM. Low-intensity pulsed ultrasound accelerates and a nonsteroidal anti-inflammatory drug delays knee ligament healing. *American Journal of Sports Medicine*. 2006;**34**:1094-1102
- [60] Warden SJ. Cyclo-oxygenase-2 inhibitors: Beneficial or detrimental for athletes with acute musculoskeletal injuries? *Sports Medicine*. 2005;**35**:271-283
- [61] Ziltener JL, Leal S, Fournier PE. Non-steroidal anti-inflammatory drugs for athletes: An update. *Annals of Physical and Rehabilitation Medicine*. 2010;**53**:278-282
- [62] Paoloni JA, Milne C, Orchard J, Hamilton B. Non-steroidal anti-inflammatory drugs in sports medicine: Guidelines for practical but sensible use. *British Journal of Sports Medicine*. 2009;**43**:863-865
- [63] Radi ZA, Khan NK. Effects of cyclooxygenase inhibition on bone, tendon, and ligament healing. *Inflammation Research*. 2005;**54**:358-366
- [64] Wiggins M, Fadale PD, Barrach H, Ehrlich MG, Walsh WR. Healing characteristics of a type-1 collagenous structure treated with corticosteroids. *American Journal of Sports Medicine*. 1994;**22**:279-288
- [65] Walsh WR, Wiggins PD, Fadale PD, Ehrlich MG. Effects of a delayed steroid injection on ligament healing using a rabbit medial collateral ligament model. *Biomaterials*. 1995;**16**:905-910
- [66] Wiggins ME, Fadale PD, Ehrlich MG, Walsh WR. Effects of local injection of corticosteroids on the healing ligaments. A follow-up report. *Journal of Bone & Joint Surgery*. 1995;**77A**:1682-1691
- [67] Nichols AW. Complications associated with the use of corticosteroids in the treatment of athletic injuries. *Clinical Journal of Sport Medicine*. 2005 Sep;**15**(5):370-375
- [68] Fadale PD, Wiggins ME. Corticosteroid injections: Their use and abuse. *Journal of the American Academy of Orthopaedic Surgeons*. 1994;**2**:133-140
- [69] Mayo Clinic. Cortisone shots. <http://www.mayoclinic.org/tests-procedures/cortisone-shots/details/risks/cmc-20206857> [Accessed: October 10, 1917]
- [70] Hauser RA. The deterioration of articular cartilage in osteoarthritis by corticosteroid injections. *Journal of Prolotherapy*. 2009;**1**(2):107-123
- [71] Shapiro PS, Rohde RS, Froimson MI, Lash RH, Postak P, Greenwald AS. The effect of local corticosteroid or ketorolac exposure on histologic and biomechanical properties of rabbit tendon and cartilage. *Hand (N Y)*. 2007;**2**(4):165-172

- [72] Wernecke C, Braun HJ, Dragoo JL. The effect of intra-articular corticosteroids on articular cartilage. A systematic review. *Orthopaedic Journal of Sports Medicine*. 2015;**3**(5):1-7
- [73] Oxlund H. The influence of a local injection of cortisol on the mechanical properties of tendons and ligaments and the indirect effect on skin. *Acta Orthopaedica Scandinavica*. 1980;**51**(2):231-238
- [74] Rabago D, Slattengren A, Zgierska A. Prolotherapy in primary care practice. *Prim Care*. 2010;**37**(1):65-80
- [75] Rabago D, Patterson JJ. Prolotherapy: An effective adjunctive therapy for knee osteoarthritis. *Journal of the American Osteopathic Association*. 2013;**113**(2):122-123
- [76] Polukhin E. Prolotherapy, myths and the truth. *Alternative and Integrative Medicine*. 2013;**2**(3):114
- [77] Distel LM, Best TM. Prolotherapy: A clinical review of its role in treating chronic musculoskeletal pain. *PM & R: The Journal of Injury, Function, and Rehabilitation*. 2011 Jun; **3**(6 Suppl 1):S78-S81
- [78] Hackett GS, Hemwall GA, Montgomery GA. Ligament and tendon relaxation treated by prolotherapy. 5th edition. Oak Park, IL; 1993
- [79] Goswami A. Prolotherapy. *Journal of Pain & Palliative Care Pharmacotherapy*. 2012 Dec; **26**(4):376-378
- [80] Reeves KD. Sweet relief: Prolotherapy targets sprains and strains. *Biomechanics*. 2004;**9**: 24-35
- [81] Reeves KD. Prolotherapy for patients with musculoskeletal disorders. *Journal of Musculoskeletal Medicine*. Oct 2002:390-301
- [82] Reeves KD. Prolotherapy: Basic science, clinical studies, and technique. In: Lennard TA, editor. *Pain Procedures in Clinical Practice*. 2nd ed. Philadelphia, PA: Hanley & Belfus; 2000. pp. 172-190
- [83] Dorman T. Prolotherapy: A survey. *Journal of Orthopaedic Medicine*. 1993;**15**:49-50
- [84] Dorman T. *Prolotherapy in the Lumbar Spine and Pelvis*. Philadelphia, PA: Hanley & Belfus; 1995
- [85] Creaney L, Hamilton B. Growth factor delivery methods of sports injuries: The state of play. *British Journal of Sports Medicine*. 2008;**42**(5):314-320
- [86] Tabata Y. Tissue regeneration based on growth factor release. *Tissue Engineering*. 2003; **9**(Suppl 1):S5-S15
- [87] Alsousou J, Thompson M, Hulley P, Noble A, Willett K. The biology of platelet-rich plasma and its application in trauma and orthopaedic surgery: A review of the literature. *Journal of Bone and Joint Surgery. British Volume*. 2009;**91**(8):987-996

- [88] Hackett G. Back pain following trauma and disease—Prolotherapy. *Military Medicine*. Jul 1961;517-525
- [89] Hackett G. Prolotherapy in whiplash and low back pain. *Postgraduate Medicine*. 1960; 27:214-219
- [90] Liu Y, Tipton CM, Matthes RD, Bedford TG, Maynard JA, Walmer HC. An in situ study of the influence of a sclerosing solution in rabbit medial and collateral ligaments and its junction strength. *Connective Tissue Research*. 1983;2(2-3):95-102
- [91] Maynard J, Pedrini VA, Pedrini-Mille A, Romanus B, Ohlerking F. Morphological and biomechanical effects of sodium morrhuate on tendons. *Journal of Orthopaedic Research*. 1985;3(2):236-248
- [92] Lyftogt J. Prolotherapy for recalcitrant lumbago. *Australia's Musculoskeletal Medicine*. 2008;13:18-20
- [93] Lyftogt J. Subcutaneous prolotherapy for Achilles tendinopathy: The best solution? *Australia's Musculoskeletal Medicine*. 2007;12:107-109
- [94] Yoshii Y, Zhao C, Schmelzer JD, Low PA, An K-N, Amadio PC. The effects of hypertonic dextrose injection on connective tissue and nerve conduction through the rabbit carpal tunnel. *Archives of Physical Medicine and Rehabilitation*. 2009;90(2):333-339
- [95] Refai H, Altahhan O, Elsharkawy R. The efficacy of dextrose prolotherapy for temporomandibular joint hypermobility: A preliminary prospective, randomized, double-blind, placebo-controlled clinical trial. *Journal of Oral and Maxillofacial Surgery*. 2011 Dec;69(12): 2962-2970
- [96] Gulses A, Bayar GR, Aydintug YS, Sencimen M, Erdogan E, Agaoglu R. Histological evaluation of the changes in temporomandibular joint capsule and retrodiscal ligaments following autologous blood injection. *Journal of Cranio-Maxillo-Facial Surgery*. 2013; 41(4):316-320
- [97] Reeves KD, Lyftogt J. Prolotherapy. In: Waldman SD, editor. *Pain Management*. 2nd ed. Philadelphia, PA: Elsevier; 2011. pp. 1044e1-1044e69
- [98] Alderman D, Alexander RW. Advances in regenerative medicine: High-density platelet-rich plasma and stem cell prolotherapy for musculoskeletal pain. *Practical Pain Management*. 2011;11(8):49-52
- [99] Linetsky FS, Miguel R, Torres F. Treatment of cervicothoracic pain and cervicogenic headaches with regenerative injection therapy. *Current Pain and Headache Reports*. 2004;8(1): 41-48
- [100] Linetsky FS, Alfredson H, Crane D, Centeno CJ. Treatment of chronic painful musculoskeletal injuries and diseases with regenerative injection therapy (RIT): Regenerative injection therapy principles and practice. In: Deer TR, Leong MS, Buvanendran A, et al., editors. *Comprehensive Treatment of Chronic Pain by Medical, Interventional, and Integrative Approaches*. New York, NY: Springer; 2013. pp. 889-912

- [101] Hauser R, Hauser M. *Prolo Your Sports Injuries Away!* Oak Park, IL: Beulah Land Press; 2001
- [102] Hauser, R, Hauser M. *Prolo your Pain Away!* 3rd Ed. Oak Park, IL: Beulah Land Press; 2007
- [103] Jacks A, Lumbosacral BT. Prolotherapy: A before-and-after study in an NHS setting. *International Musculoskeletal Medicine*. 2012;**34**(1):12-17
- [104] Dumais R, Benoit C, Dumais A, et al. Effect of regenerative injection therapy on function and pain in patients with knee osteoarthritis: A randomized crossover study. *Pain Medicine*. 2012 Aug;**13**(8):990-999
- [105] Hauser RA, Sprague IS. Outcomes of prolotherapy in chondromalacia patella patients: Improvements in pain level and function. *Clinical Medicine Insights. Arthritis and Musculoskeletal Disorders*. 2014;**7**:13-20
- [106] Mora MV, Iban MA, Heredia JD, et al. Stem cell therapy in the management of shoulder rotator cuff disorders. *World Journal of Stem Cells*. 2015;**7**:691-699
- [107] Gregori LM, La Marra A, Arrigoni F, Zugaro L, Barile A, Masciocchi C. Four-year experience follow-up in the treatment of degenerative disease of the supraspinatus tendon by ultrasound guided injections of PRP. Paper Presented at: Radiological Society of North America. 2013; Chicago, IL
- [108] Tsatsos G, Mandal R. Prolotherapy in the treatment of foot problems. *Journal of the American Podiatric Medical Association*. 2002;**92**(6):366-368

IntechOpen

